

Case Report

Laparoscopic approach of hepatic hydatid double cyst in pediatric patient: difficulties, indications and limitations

Isabela M. Drăghici^{1,2}, Maria D. Popescu¹, Constantin C. Pătru¹, Anca M. Raicu²,
Roxana Boloagă², Liviu Drăghici^{1,3}

¹Carol Davila University of Medicine and Pharmacy, Bucharest, Romania

²Maria Sklodowska Curie Emergency Clinical Hospital, Department of Pediatric Surgery, Bucharest, Romania

³Sf. Ioan Emergency Clinical Hospital, Department of General Surgery, Bucharest, Romania

Abstract

Purpose: Laparoscopic management analysis of a rare condition having potentially severe evolution, seen in pediatric surgical pathology.

Aims: Outlining the optimal surgical approach method of hepatic hydatid double cyst and the laparoscopic method's limitations.

Materials and Methods: The patient is a 6 years old girl that presented with two simultaneous giant hepatic hydatid cysts (segments VII-VIII), having close vicinity to the right branch of portal vein and to hepatic veins; she benefited from a single stage partial pericystectomy Lagrot performed by laparoscopy.

Results: The procedure had no intraoperative accidents or incidents. Had good postoperative evolution without immediate or late complications. Trocars positioning had been adapted to the patient's size and cysts topography.

Conclusions: The laparoscopic treatment is feasible and safe, but is not yet the gold standard for a hepatic hydatid disease due to certain inconveniences.

Keywords: laparoscopy, hydatid cyst, paediatric patients, indications



Introduction

Although in many European countries the disease has been eradicated thus the surgical technique is less known, in Romania we still have cases of hepatic hydatid cysts sometimes with multiple localizations. In Romania, the frequency of hydatid hepatic disease is 5/100 000 population.

Multiple localizations can make the approach difficult both in classic and laparoscopic surgery (1). Not without importance is the antiparasitic albendazole treatment: disseminated disease, inoperable cases or prophylaxis before surgery to sterilize the cyst and to minimize the effects of potential spillage during the operation (2-4).

The surgical treatment usually follows the pharmaceutical one and has the problem of tactic and technical approach especially for multiple localizations. It is the only radical method of curing the hydatid disease. At the same time, it must be successively to the medical treatment. It requires a good preoperative preparation with vitamins treatment, hepatoprotective treatment, antihistamine prophylaxis.

Case Report

The case is that of a little girl, age six, that presented with two simultaneous giant hepatic hydatid cysts (segments VII-VIII), having close vicinity to the right branch of portal vein and to hepatic veins. Computed tomography performed with contrast solution confirmed the diagnosis and localization of lesions (Figure 1).

Laparoscopic instruments are the usual: 30°-degree telescope, 10 mm optic trocar, 3 working trocar (one of 10 mm and two of 5 mm), laparoscopic puncture needle, irrigation/ aspiration system – 5mm aspiration cannula, 10 mm rigid rod, rounded, useful for instrumental control, 2-3 apprehension forceps, 1 Maryland forceps (useful to easily extract the proligere membrane), 2 needle forceps, the monopolar hook, scissors, Liga-Sure™ forceps or Harmonic Scalpel.

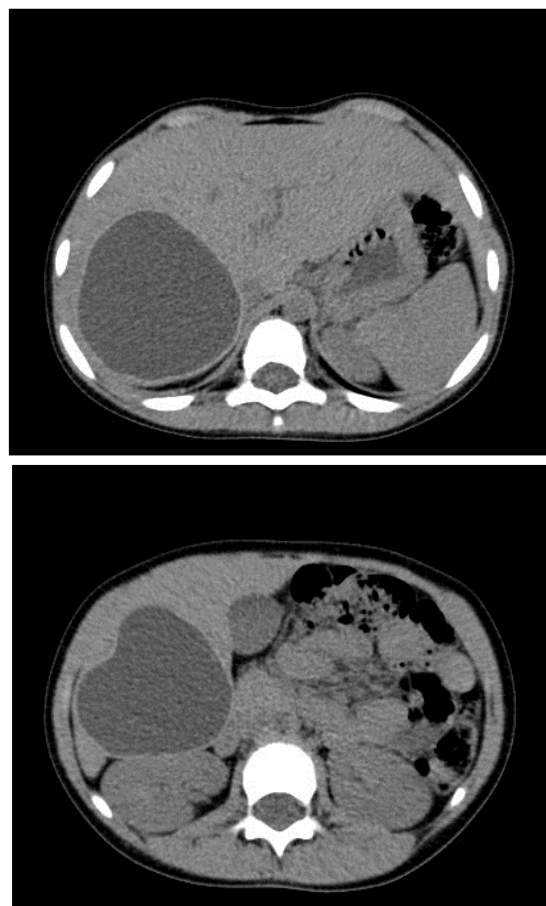

Figure 1. Two simultaneous giant hepatic hydatid cysts - segments VII-VIII

Setting of the patient and surgical team (Figure 2) consisted of the patient who is positioned in reverse Trendelenburg and Redick position (operator on the left side of the patient, cameraman left of the operator and the help on the opposite side) (Figure 2a); possible occurrence of certain difficulties positioning in small patients; the operation can be performed by 2 surgeons (cameraman is required to hold the liver spreader using the left hand).

Trocars placement is determined by the site of the lesion and dimensions of the patient. These are: umbilical optic trocar of 10 mm (1), working trocars introduced parallel to the ribs on the lesion side, working trocar of 10 mm for the active instrument (“right hand trocar”) – left/right quadrate or epigastric (2 or 5), two working trocars of 5mm in the upper and lower quadrate of the lesion for: apprehension forceps, liver spreader, puncture needle, aspiration cannula (3 and 4) (Figure 2b).

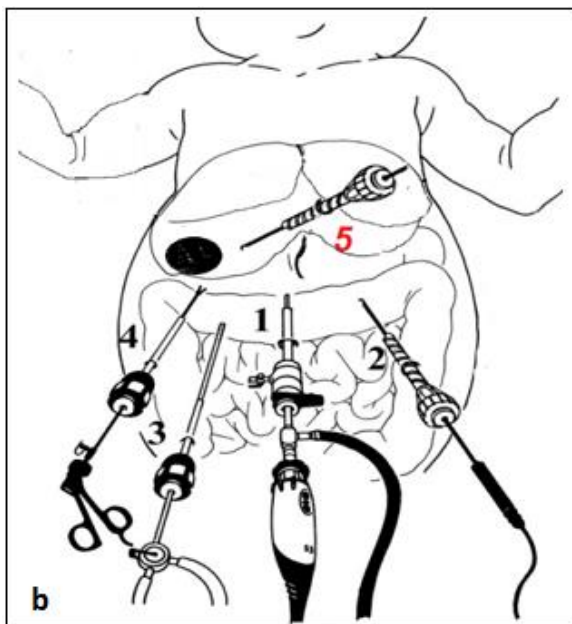
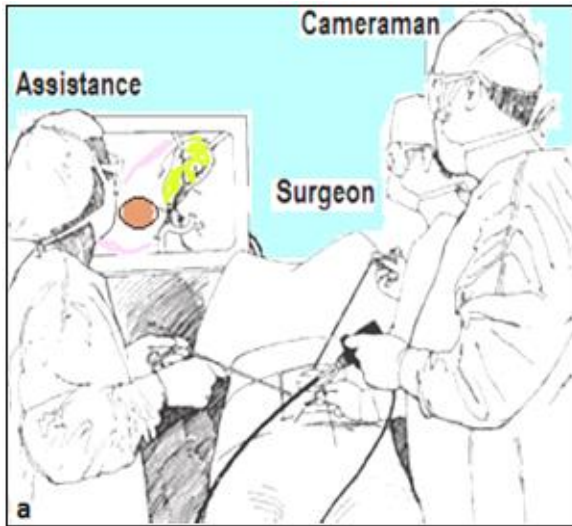


Figure 2. The surgical team and trocars position (Draghici I, 2014. Laparoscopic treatment of hepatic hydatid cyst in children, ISBN 978-9975-74-716-5)

The operating times and surgery steps are well established: insufflation of pneumoperitoneum, exploration of the peritoneal cavity, treatment of the parasite (inactivation), evacuation of the cyst material and prevention of spillage, treatment of the cyst, pericystectomy, drainage of the remaining cavity.

We conducted the following sequence of treatment: laparoscopic puncture (Figure 3a), the aspiration fluids contained in the internal germinal membrane (Figure 3b), instillation of a small amount of saline solution as a fluid replacement (Figure 3c) and then waited 15 minutes (Figure 3d), followed by

the evacuation of the germinal membrane (Figure 4) and pericystectomy (Figure 5).

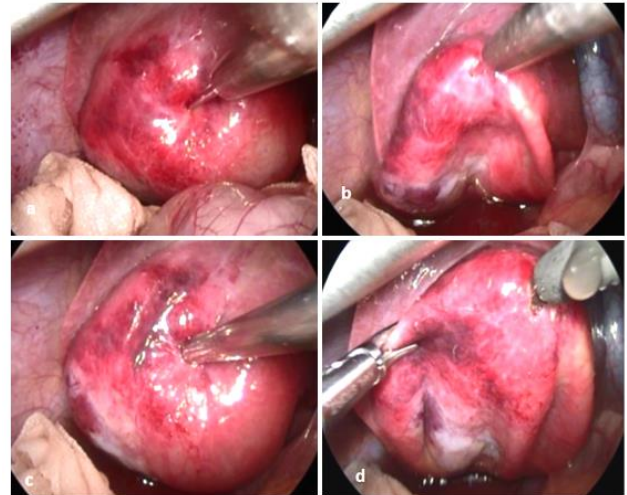


Figure 3. Puncture of hydatid cyst – the most important stages (Draghici I, 2014. Laparoscopic treatment of hepatic hydatid cyst in children, ISBN 978-9975-74-716-5)

Our presentation included the major operating steps beginning with the placement of trocars and liver lobe retraction. Identification of the cyst localized in segment VII was easy, unlike for the posterior one, where we had two attempts to puncture. Using the 10-mm epigastric trocar we inserted a mesh soaked in hypertonic saline solution required for the isolation of the operative field. The same 10-mm trocar will be used in order to insert the endo-bag. After that we perform the puncture of the cyst (Figure 3a) without excessive pushing the needle in order not to cause liver hemorrhage. For inactivation of the contents we used hypertonic saline solution or absolute alcohol (Figure 3b). After the extraction of the content we performed cystotomy (Figure 4) and extracted the germinate membrane that is inserted into the endo-bag.

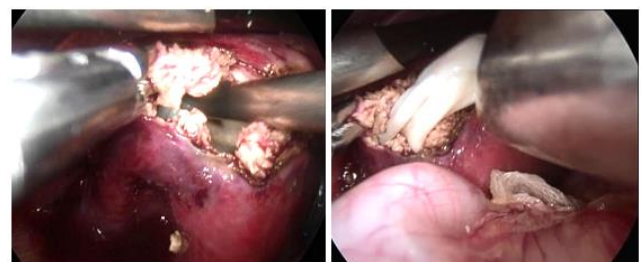


Figure 4. Opening of the cyst - approach the internal germinal membrane (Draghici I, 2014. Laparoscopic treatment of hepatic hydatid cyst in children, ISBN 978-9975-74-716-5)

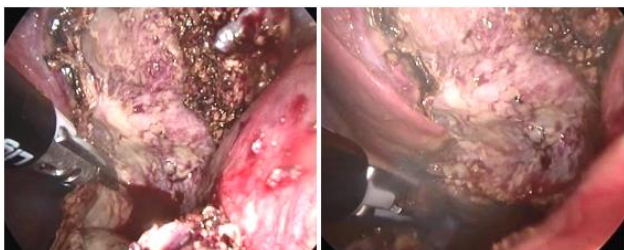

Figure 5. Pericystectomy performed with LigaSure (Draghici I, 2014. Laparoscopic treatment of hepatic hydatid cyst in children, ISBN 978-9975-74-716-5)

With the Liga-Sure forceps we performed pericystectomy (Figure 5) then the inspection of the remaining cavity. There is a risk of electrical damage to the neighbouring viscera, such as the colon and duodenum, but they occur only when exposure is incomplete and visibility of the area is low. The parts were extracted using the endo-bag through a gate of 10 mm. As we mentioned, the lesion in segment VIII was deep and raised the approach issues. The cyst was punctured through a 10 mm trocar in the epigastrium and forceps controlled from the trocar in the right flank. Neighbouring suprahepatic veins and diaphragmatic vessels increase the risk of bleeding lesions at this level, both during cyst puncture and while performing cystectomy with forceps Liga-Sure.

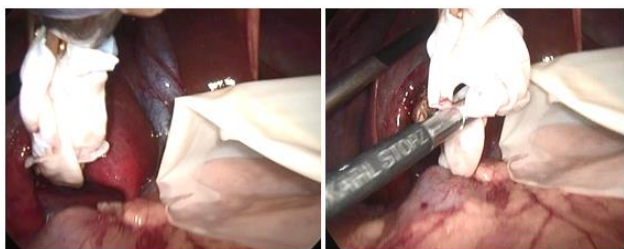


Figure 6. Extracting the germinate membrane that is inserted into the endo-bag/ glove (Draghici I, 2014. Laparoscopic treatment of hepatic hydatid cyst in children, ISBN 978-9975-74-716-5)

For this reason, we can perform the dissection using a fine instrument such as monopolar hook. Inspection and drainage of residual cavity at this level are sometimes difficult, but not impossible. The operation was completed with overall control of the peritoneal cavity, lavage and drainage.

Important is the usage of the endo-bag (Figure 6) in order to collect the extracted parts. The daughter

vesicles are extremely dangerous and high risk of spillage is possible.

Discussion

The surgical treatment raises the issue of tactics and technique. It is a laborious surgery through various manoeuvres by: organ punctures, exploratory surgery, resections, drainage, anastomosis, surgery for hydatid recurrences etc. requires a good experience in laparoscopic surgery (5).

Like any pathology that has an unforeseeable evolution the hepatic hydatid cyst has the risk of recurrence. Among conservative procedures should be listed: simple drainage, unroofing, introflexion, omentoplasty etc. The most common are radical procedures, such as: partial cystectomy, pericystectomy Lagrot and hepatic resections. A much discussed issue refers to utility of surgery for hydatid recurrence after radical interventions.

The aim of surgery is to determine whether the operation can be performed by laparoscopic method. Under what conditions? The laparoscopic treatment of the hydatid cyst has the same approach principles as the classic surgery. It needed a complete evacuation of the cyst without leakage, followed by sterilization and cavity obliteration. The difficulties concern technical problems, such as: intraparenchymal cysts, which do not reach the surface of the liver (difficult to localize and manage laparoscopically); multiple cysts; posterior localization with difficult laparoscopic access; the cysts in an advanced stage, such as those with calcified walls, may cause cavity-related problems after surgery.

In conclusion the principles of classical surgery must be respected, including field isolation and method of operation.

Relative contraindications of the laparoscopic procedure are: the existence of more than three cysts, profound intraparenchymal localization, posterior localization, cysts with thick and calcified walls, cysts characterized by heterogeneous complex mass (Gharbi

type 4) (6), cyst less than 3 cm in diameter and serious coagulation abnormalities.

The most important advantages of the laparoscopic treatment are: perfect isolation of the abdominal wall (no laparotomy), isolation of the operative field using sterile tissue (wet packs) sulked with a 10% saline hypertonic solution introduced through the 10 mm trocar, perfect view of the cyst– intraoperative diagnosis of the biliary fistula larger than 2-3 mm in diameter, hemostasis and efficient biliary stasis, hospitalization period is reduced compared to that following open surgery.

Contrary to general enthusiasm, there are still some disadvantages such as: the need to perform a manual control of the profound cysts (instrumental control of the profound intraparenchymal cysts more difficult than the manual control), need to perform a eventually intraoperative laparoscopic ultrasonography, difficult or impossible approach of the posterior and profound cysts, limitation regarding biliary-digestive and cystic-digestive anastomosis, which requires special training of minimally invasive surgery for applying manual and mechanical techniques of laparoscopic suture.

There is no standard position of the trocars, this depending of the lesion position and the dimensions of the patient. The most important laparoscopic gesture is the puncture and sterilization of the hepatic cyst contain. Bickel et al. concluded that simple needle aspiration fails to prevent spillage (7, 8).

Exploration and pericystic cavity lavage with saline are mandatory at the end of surgery. Drainage of the residual cavity ends the surgery. A video endoscopic control of the remaining cavity is performed in order to look for biliary fistulas. Search for biliary fistula is an underestimated problem: biliary communications require their preoperative detection. Laparoscopic cholecystectomy using an external

transcystic biliary drainage can be a solution to a biliary fistula.

In case of important biliary fistulas, a transcystic extern biliary drainage is recommended followed by an ERCP (endoscopic retrograde cholangio-pancreatography) with EPS (endoscopic papillary sphincterectomy). It is believed that centrally located large cysts are more prone to this complication than the peripherally located smaller cysts. This complication may be solved with early endoscopic nasobiliary stenting or, as we prefer, with endoscopic sphincterotomy (7, 8). In contrast to the opinions against the routine use of a closed suction drainage catheter (9, 10), our experience in surgical treatment of hydatid disease of the liver urges us to routinely use short-term drainage in all cases.

We acknowledged as the most important postoperative complications (11):

- External biliary fistula
 - conservative therapy when the daily bile output is < 300 ml, replacing the patient's daily fluids and electrolyte losses;
 - high-output fistulas > 300 ml more than 1-week duration and low output fistulas of more than 3 weeks duration were treated by endoscopic sphincterotomy.
- Anaphylactic shock due to spillage caused during puncture cyst manoeuvre;
- Bleeding;
- Post-operative infection with creating of perihepatic abscesses;
- Recurrence (later complication).

The laparoscopic procedure for hydatid hepatic disease has an important limitation due to the positioning of the cyst, encountered during open surgery as well.

Biliary fistula remains a certain indication for a biliary drainage (E.R.C.P and EPS for a small fistula orifice or digestive-pericystic derivation for a high

output fistula). When finding a fistula, conversion to open surgery is required.

Laparoscopic surgery has, for now, a limited possibility for: performing a hepatic resection and suture, solving a biliary ducts spillage, executing a biliary-digestive anastomosis or for treating a critical deforming perivisceritis. Because it is a rare pathology, the learning curve is difficult to surpass. Because of the risk of developing postoperative complications (recurrence) is questionable indication for open surgery laparoscopic approach.

Conclusions

The laparoscopic treatment is feasible and safe, but is not yet the gold standard for a hepatic hydatid disease due to the mentioned inconveniences.

References

1. Ran B, Shao Y, Yimiti Y, Aji T, Jiang T, Cheng L, Li W, Zhang W, Wen H. Surgical Procedure Choice for Removing Hepatic Cysts of Echinococcus granulosus in Children. *Eur J Pediatr Surg.* 2016; 26(4): 363-7. PMID: 26479421
<https://doi.org/10.1055/s-0035-1554806>
2. Horton RJ. Chemotherapy of Echinococcus infection in man with albendazole. *Trans R Soc Trop Med Hyg.* 1989; 83(1): 97-102. PMID: 2603216
[https://doi.org/10.1016/0035-9203\(89\)90724-4](https://doi.org/10.1016/0035-9203(89)90724-4)
3. Kanojia RP. Laparoscopic port-in-cyst technique for retrieval of hepatic hydatid and review of other techniques used in literature. *J Pediatr Surg.* 2012; 47(9): 1772-4. PMID: 22974623
<https://doi.org/10.1016/j.jpedsurg.2012.05.021>
4. Cakmakci M, Sayek I. Prophylactic effect of albendazole in experimental peritoneal hydatidosis. *Hepatogastroenterology* 1992; 39(5): 424-6.
5. Muhtarov M, Rainova I, Tamarozzi F. Treatment of Hepatic Cystic Echinococcosis in Patients from the Southeastern Rhodope Region of Bulgaria in 2004-2013: Comparison of Current Practices with Expert Recommendations. *Am J Trop Med Hyg.* 2016; 94(4): 900-5. PMID: 26834196
<https://doi.org/10.4269/ajtmh.15-0620>
6. Mohan S1, Garg SK, Kathuria M, Baijal SS. Mechanical suction through wide bore catheters for nonsurgical management of Gharbi type III hepatic hydatid cysts. *Trop Gastroenterol.* 2011; 32(3): 189-95. PMID: 22332334
7. Koca T, Dereci S, Gençer A, Duman L, Aktaş AR, Akçam M, Akçam FZ. Cystic Echinococcosis in Childhood: Five-Years of Experience From a Single-Center. *Turkiye Parazitol Derg.* 2016; 40(1): 26-31. PMID: 27222332
<https://doi.org/10.5152/tpd.2016.4381>
8. Padhy B.P, Hota P.K. Laparoscopic management of a large hydatid cyst of liver (case report). *Bali Med J.* 2015; 4(3): 140-142.
<https://doi.org/10.15562/bmj.v4i3.156>
9. Nabil S, Bentalha A, Jaiteh L, El Khorassani M, El Koraichi A, El Kettani SE. Hydatid cyst surgery complicated by hemorrhage resistant to activated recombinant factor VII, in a hemophiliac A patient with an inhibitor. *Blood Coagul Fibrinolysis.* 2016; 27(6): 724-6. PMID: 26761579
<https://doi.org/10.1097/MBC.0000000000000470>
10. Demirci S, Eraslan S, Anadol E, Bozatli L. Comparison of the results of different surgical techniques in the management of the hydatid disease of the liver. *World J Surg.* 1989; 13(1): 88-91. PMID: 2728465
<https://doi.org/10.1007/BF01671161>
11. Oral A, Yigiter M, Yildiz A, Yalcin O, Dikmen T, Eren S, Kantarci M, Salman AB. Diagnosis and management of hydatid liver disease in children: a report of 156 patients with hydatid disease. *J Pediatr Surg.* 2012; 47(3): 528-34. PMID: 22424349
<https://doi.org/10.1016/j.jpedsurg.2011.11.007>