



Case Report

Vulvar basal cell carcinoma, a rare location

Cornelia Nitipir^{1,2}, Iulian Slavu^{3*}, Cristina Orlov², Raluca Tulin¹, Luminita Tomescu³, Adrian Tulin^{1,3}

¹Carol Davila University of Medicine and Pharmacy, Bucharest, Romania

²Elias University Emergency Hospital, Department of Oncology, Bucharest, Romania

³Agrippa Ionescu Emergency Hospital, Department of General Surgery, Bucharest, Romania

Abstract

Basal Cell Carcinoma is the most common human malignant neoplasm. Vulvar basal cell carcinoma is rare, accounting for less than 5% of all vulvar neoplasms. Vulvar basal cell carcinomas are usually diagnosed late because they are often asymptomatic and tend to grow at slow rates. They are usually diagnosed late because they are often asymptomatic. However, these tumours may appear in areas which are normally covered with ultraviolet light.

We present the case of a 60 years old woman diagnosed with invasive breast cancer for which she underwent surgery followed by chemotherapy and radiotherapy. The patient presented to our department with an ulcerated vulvar lesion. On inspection, the tumour measured 3/2 cm and was located on the left labium majus. The biopsy confirmed the diagnosis of vulvar basal cell carcinoma and a wide local excision was performed with no relapse at one year.

In conclusion, early detection of BCC's is critical to allow complete surgical cure so any abnormality on the vulva should be biopsied. A wide safety margin of 1cm should be achieved when resecting the tumour and the physician should keep in mind that the BCC's of the vulva has a high recurrence rate. Previous chemotherapy is not associated with this type of non-melanoma skin cancer.

Keywords : vulvar, basal cell carcinoma, chemotherapy, rare location

Highlights

- ✓ A complete/ oncological resection of vulvar basal cell carcinoma implies an early detection, which is possible through a precocious biopsy of any new suspect lesions
- ✓ BCC's of the vulva has a high recurrence rate, so that a wide resection margin (1cm or more) should be performed for a safety excision.

To cite this article: Nitipir C, Slavu I, Orlov C, Tulin R, Tomescu L, Tulin A. Vulvar basal cell carcinoma, a rare location. *J Clin Invest Surg.* 2018; 3(1): 53-56. DOI: 10.25083/2559.5555/31.5356

Introduction

Basal-cell carcinoma (BCC) is one of the most common types of cancers found. Incidence increases with age but the development is conditioned by the duration of lifetime exposure to ultraviolet radiation, so 85% of these are found in areas exposed to the sun such as head or neck but they can be found in rare situations in less exposed areas where the lesions are hard to identify.

These rare locations are: perianal locations, axilla or vulva (1). Since its first description by Temesvary in 1926, 200 cases of vulvar BCC have been listed in the literature. BCC vulvar accumulates below 1% of all BCCs and less than 5% of all vulvar cancers, and it is more common in menopausal women (2, 3).

Clinically vulvar BCC is a tumour with indolent and destructive local development, which can rarely metastasize, but the rate of local recurrence can reach 20% (4, 5).

Case report

We present the case of 60-year-old woman who presented with vulvar itching and spontaneous genital bleeding, manifestations which debuted about six weeks before presentation. From her medical history, the patient underwent two years before left Madden mastectomy with axillary lymphodissection for breast cancer which was followed by adjuvant chemotherapy and radiotherapy. She underwent four courses of doxorubicin and cyclophosphamide and four courses of docetaxel. She then received chest wall radiation to a total dose of 50.4 Gy in 28 fractions.

At the time of presentation, she was treated with hormonal therapy: letrozole 2.5 mg daily. She had no family history of skin cancer. Physical examination revealed a 3/2 cm indurated area with elevated margins, ulcerated, located on the left labium majus oriented to the exterior.

There were no palpable inguinal lymph nodes or other macroscopic lesions in the genital area. A punch biopsy was done which revealed: basaloid epithelial tumour cells arising from the epidermis, arranged in palisade with a cleft forming from the adjacent tumour stroma, single cell necrosis with scattered mitotic figures and necrotic bodies, cytologic atypia, typical of basal cell carcinoma, nodular type, tumour stage T1NXMX. (Figure 1).

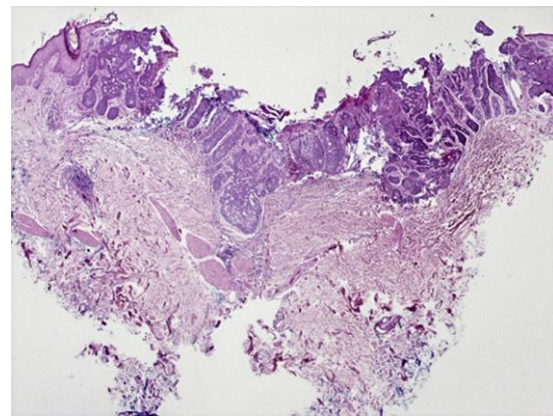


Figure 1. Multilobular tumour arising from the epidermis, composed of basaloid epithelial cells. Hematoxylin and eosin; original magnification X20

A wide local excision was performed with 1 cm oncologic safety margins. In the final pathology examination, there was no residual disease (R₀) and no extension of the tumour in the underlying structures with no lymphovascular penetration (pT₁N_x). At one year follow up the surgical site had healed completely with no local recurrence.

Discussion

The most important risk factor for the increased incidence of BCC is directly related to intense exposure to ultraviolet radiation (6). The reasons why this disease appears in areas which are not exposed to sunlight is still debated. Various factors have been incriminated such as: chronic vulvar irritation (e.g. long-term use of diapers), ionizing radiation, arsenic, chronic inflammation, hamartomas, immune deficiency and genetic alterations: Activation of the hedgehog signaling pathway leading to overexpression of GLI1 or GLI2 gene production, loss of function mutations of PTCH1 or PTCH2, activating mutations of SMO, also p53 mutations have been identified in many cases (5).

The disease usually affects older women with ages varying from 34 years to 96 years but with an average of 70 years (5). Due to its hidden location, diagnosis is usually late; symptoms are non-specific while patients tend to be older in age and don't observe the disease's manifestations. The most common signs are itching and local irritation. The time from the onset of symptoms to diagnosis ranges from a few months to several years (1). The tumours often have the visual aspect of a nodule or ulcer but they can also manifest as various dermatological diseases like eczema, psoriasis or seborrheic keratosis. Whenever in doubt, biopsy is the best approach. Due to its embryologic origin, these

tumours very really metastasize and evolve locally with slow growth so local surgical excision with oncologic margins of 1 cm usually suffices as a definitive treatment (8). The vulva is considered a high-risk region regarding the relapse rate of BCC when compared to other regions of the body, because the local tissue is harder to differentiate from the diseased one and frequently the safety margins are committed, so when possible a larger area of resection should be preferred or Mohs micrographic surgery should to be taken into account to ensure the best results for the patient (9, 10).

Metastasis is rarely encountered, in under 0.1% of cases and is usually distributed to the inguinal lymph nodes but tumoral cells can be found in other sites such as skin, bone or lung. The systemic disease is favored by a large tumour, usually above 2cm (11, 12). Postoperative radiotherapy is an option in selected cases. Local wide excision remains the mainstay primary treatment even for recurrence (13).

In our case, the hypothesis of chemotherapy induced non-melanoma skin cancer rose. However, in a case-control clinical trial by Rubino et al., no association was found between chemotherapy and non-melanoma skin cancer (14). The possibility that adjuvant chemotherapy influenced the aetiology of the skin cancer, in this case, is therefore low.

Conclusions

In conclusion, early detection of BCC's is critical to allow complete surgical cure so any abnormality on the vulva should be biopsied. A wide safety margin of 1cm should be achieved when resecting the tumour and the physician should keep in mind that the BCC's of the vulva has a high recurrence rate. Previous chemotherapy is not associated with this type of non-melanoma skin cancer.

References

1. de Giorgi V, Salvini C, Massi D, Raspollini MR, Carli P. Vulvar basal cell carcinoma: retrospective study and review of literature. *Gynecol Oncol.* 2005; 97(1): 192–4. PMID: 15790457, DOI: 10.1016/j.ygyno.2004.12.008
2. Asuman C, Ozlem A, Burcak T, Onder P. An unusual location of basal cell carcinoma: The clitoris and the vulva. *Indian J Dermatol.* 2008; 53(4): 192-4. PMID: 19882033, DOI: 10.4103/0019-5154.44795
3. Pisani C, Poggiali S, De Padova L, Andreassi A, Bilenchi R. Basal cell carcinoma of the vulva. *J Eur Acad Dermatol Venereol.* 2006; 20(4): 446–8. PMID: 16643146, DOI: 10.1111/j.1468-3083.2006.01456.x
4. Piura B, Rabinovic A, Dgani R. Basal cell carcinoma of the vulva. *J Surg Oncol.* 1999; 70(3): 172-6. PMID: 10102347
5. Benedet JL, Miller DM, Ehlen TG, Bertrand MA. Basal cell carcinoma of the vulva: Clinical features and treatment results in 28 patients. *Obstet Gynecol.* 1997; 90(5): 765-8. PMID: 9351761 DOI: 10.1016/S0029-7844(97)00416-X
6. Rubin AI, Chen EH, Ratner D. Basal-cell carcinoma. *N Engl J Med.* 2005; 353(21): 2262-9. PMID: 16306523, DOI: 10.1056/NEJMra044151
7. Feakins RM, Lowe DG. Basal cell carcinoma of the vulva: a clinicopathologic study of 45 cases. *Int J Gynecol Pathol.* 1997; 16(4): 319–24. PMID: 9421070
8. Gibson GE, Ahmed I. Perianal and genital basak cell carcinoma: A clinicopathologic review of 51 cases. *J Am Acad Dermatol.* 2001; 45(1): 68-71. PMID: 11423837, DOI: 10.1067/mjd.2001.114588
9. Mulayim N, Foster Silver D, Tokgay Ocal I, Babalola E. Vulvar basal cell carcinoma: two unusual presentations and review of the literature. *Gynecol Oncol.* 2002; 85(3): 532-7. PMID: 12051887
10. Bălălău DO, Sima RM, Bacalbaşa N, Banu P, Bălălău C, Pleş L, Stănescu AD. *J Mind Med Sci.* 2017; 4(1): 24-30. DOI: 10.22543/7674.41.P2430
11. Silverman MK, Kopf AW, Bart RS, Grin CM, Levenstein MS. Recurrence rates of treated basal cell carcinomas. Part 3: Surgical excision. *J Dermatol Surg Oncol.* 1992; 18(6): 471-6. PMID: 1592998
12. Suarez-Amor O, Monteagudo B, Cabanillas M, de las Heras C. Vulval location: an indication for staging in basal cell carcinoma? *Australas J Dermatol.* 2009; 50(4): 297. PMID: 19916978, DOI: 10.1111/j.1440-0960.2009.00563.x
13. Jimenez HT, Fenoglio CM, Richart RM. Vulvar basal cell carcinoma with metastasis: a case report.

- Am J Obstet Gynecol.* 1975; 121(2): 285-6. PMID: 1115140 DOI: 10.22543/7674.51.P4652
14. Feakins Bodean OM, Marcu RD, Spinu DA, Socea B, Diaconu CC, Munteanu O, Taus N, Cirstoiu M. Pelvic floor disorders in gynecological malignancies. An overlooked problem? *J Mind Med Sci.* 2018; 5(1): 46-52.
15. Rubino C, Vathaire F, Shamsaldin A, Labbe M, Radioation dose, chemotherapy, hormonal tratment and risk of second cancer after breast cancer treatment. *Br J Cancer.* 2003; 89(5): 840-6. PMID: 12942115 PMCID: PMC2394476 DOI: 10.1038/sj.bjc.6601138