



Received for publication: May 14, 2019

Accepted: July 27, 2019

## Research article

# The surgical treatment of diabetic foot ulcers

Cristina N. Marina<sup>1,2</sup>, Razvan Danciu<sup>2</sup>, Laura Raducu<sup>1,2</sup>, Razvan V. Scaunasu<sup>3</sup>, Cristian R. Jecan<sup>1,2</sup>, Petre I. Florescu<sup>1</sup>

<sup>1</sup>Carol Davila University of Medicine and Pharmacy, Department of Plastic and Reconstructive Surgery, Bucharest, Romania

<sup>2</sup>Prof. Dr. Agrippa Ionescu Emergency Clinical Hospital, Department of Plastic and Reconstructive Surgery, Bucharest, Romania

<sup>3</sup>Carol Davila University of Medicine and Pharmacy, Coltea Clinical Hospital, Department of General Surgery, Bucharest, Romania

### Abstract

Diabetic foot ulcers usually appear in diabetic patients, being associated with neuropathy, peripheral arterial disease and infection. The treatment should be initialized after stabilizing the patients in terms of glycaemia, nutritional status and systemic infections. The local treatment is started with the surgical debridement and the defect is then closed by secondary intention or by using a skin graft or local flaps. A multidisciplinary approach and proper treatment prevent in some cases complications and avoid leg amputation, thus increasing the patient's quality of life.

Amputation might be an option to the treatment when necrosis or osteomyelitis are present. On a long term, complications can arise due to the modification of the normal tension forces of the leg, with new ulcerative lesions or stress fractures. The long-term goal is to prevent injury to the affected or contralateral leg by maintaining health and glucose blood levels within normal limits and to instruct patients to maintain a proper feet care.

### Keywords

: diabetic foot ulcers, diabetes, surgical treatment, amputation

### Highlights

- ✓ Diabetic foot ulcer is a severe complication that often requires the collaboration of a multidisciplinary team.
- ✓ When necessary, surgical treatment should not be delayed, as it plays a fundamental role in preventing subsequent complications.

**To cite this article:** Marina CN, Danciu R, Raducu L, Scaunasu RV, Jecan CR, Florescu PI. The surgical treatment of diabetic foot ulcers. *J Clin Invest Surg.* 2019; 4(2): 96-100. DOI: 10.25083/2559.5555/4.2/96.100



\*Corresponding author: Razvan Danciu, Prof. Dr. Agrippa Ionescu Emergency Clinical Hospital, Department of Plastic and Reconstructive Surgery, Bucharest, Romania;

E-mails: [razvan.danciu91@gmail.com](mailto:razvan.danciu91@gmail.com), [raducu.laura@yahoo.com](mailto:raducu.laura@yahoo.com)

## Introduction

Diabetic foot represents a condition which involves diabetic patients, being characterized by the presence of infection or deep tissue destruction associated with neuropathy and arteriopathy (1). It affects 15% of the diabetic patients during their lifetime, causing soft tissue injury called ulcer (2). This severe complication precedes 85% of the amputations performed in diabetic patients, being associated with poor quality of life and a high mortality rate that can reach up to 50% in 5 years (3-5).

Ulcerative lesion formation is a process that includes several pathophysiological mechanisms. A minor injury may remain unidentified by the patient due to peripheral neuropathy, but it is increased due to local vascular suffering and may be complicated by bacterial infection. Bacteria such as *Staphylococcus aureus*, *Enterobacter*, *Pseudomonas aeruginosa*, *Escherichia coli*, *Serratia* and *Peptoniphilus* have been shown to play a role in slowing down the normal wound healing process (6).

The surgical management of diabetic foot ulcers plays an integrative role in preventing complications in diabetic patients. The early surgical intervention and antibiotic therapy are the best solutions to save the limb from amputation (7). The surgical debridement is the fastest and the most efficient method of removing necrotic and devitalized tissue. Special attention should be paid to the correct delimitation of dead tissues from healthy tissues (1). Postoperatively, patients should be closely monitored and educated to monitor their foot condition and to use the appropriate footwear (7).

## Materials and Methods

A retrospective study was conducted in the Plastic Surgery Department of "Prof. Dr. Agrippa Ionescu" Emergency Clinical Hospital, in which 30 patients with diabetic foot syndrome over a 6 month-period were enrolled. The admitted patients had plantar, dorsal and lateral foot ulcerations and toe necrosis.

Anamnesis and clinical examination had the role of evaluating the presence of diabetic foot risk factors such as history of ulceration, peripheral neuropathy, peripheral vascular disease, leg deformity or age over 65 years.

The hematological status (hemoglobin), the nutritional status (albumin) and the glycemic control (HBA1C) were assessed. Wound cultures were drawn upon admission and leg radiography was performed to assess bone

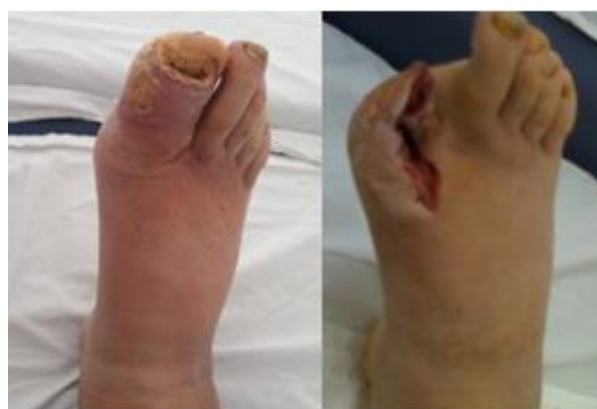involvement. The evaluation of neuropathy was done by using a 10g Semmes-Weinstein monofilament test.

## Results

26 of the patients enrolled were men and 20 of them were from rural areas. The patients' mean age was 59.36 years with a mean diabetic duration of 11.7 years.

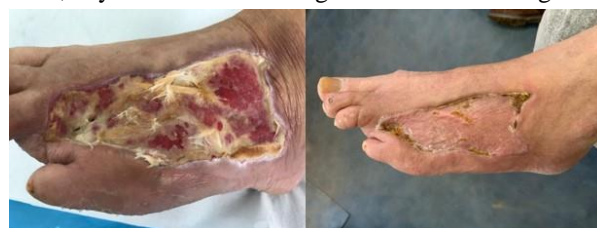The patients enrolled in the study had different types of lesions that were treated through surgical debridement or amputation. After the surgical debridement, the defect was covered using skin grafts, local flaps or by secondary healing.

In patients with toe necrosis or osteitis, amputation was necessary. The patients usually come in an advanced stage with leg infection and empiric antibiotic treatment is started after drawing wound cultures. After amputation, the defect is left open for 3-4 days, being sutured when the inflammatory signs disappear.



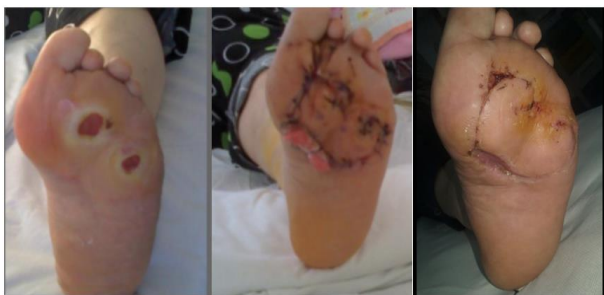
**Figure 1.** Hallux necrosis and osteitis of the right foot-necessity of amputation and secondary closure

Ulcerations present on the dorsal part of the foot are usually covered by using a skin graft, especially when the defect is large and the leg vascularization is poor. The reconstruction is performed when the wound cultures are sterile, any bacterial load being a threat to the skin graft.

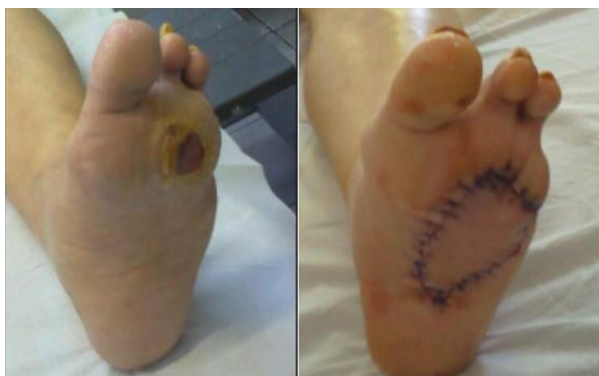

**Figure 2.** Patient with ulceration on the dorsal part of the foot covered using a split skin graft.

Plantar ulcerations on the pressure areas are usually covered by using a local flap rotated or advanced from the areas where pressure is not present. This is also performed after sterilizing the wound.



**Figure 3.** Patient with plantar ulcers that were covered by using local rotational flaps.



**Figure 4.** Plantar ulcer covered by using a local advancement flap.

Plantar ulcers usually appear over the pressure areas and that is why they are so difficult to treat. Sometimes, patients refuse surgery and the only solutions are dressings and secondary healing. Every patient with ulceration requires a radiography because this could hide an osteitic process. Secondary healing is usually time and money consuming regarding the frequency and the necessity of special dressings that are used, such as polyhexanide solution or polyurethane foam (8, 9).

## Discussions

Significant The diabetic foot is a severe complication that requires a multidisciplinary team for proper management. The diabetologist aims at balancing blood sugar levels because high levels of glucose increase blood viscosity and lower the efficiency of white blood cells. The infectious disease specialist has the role of optimizing the antibiotic therapy, the orthopedic surgeon evaluates and remedies the biomechanical abnormalities, the vascular surgeon improves the local blood flow and the plastic surgeon has the role of transforming a chronic wound into a wound that heals normally or to close the wound using plastic surgery techniques (3).

The healing process in this condition depends largely on the general status of the patient, so a proper assessment of the preoperative risk is mandatory. This includes a detailed medical history, a surgical history, a list of all

current medications and the identification of other risk factors such as smoking. From blood tests, it would be ideal to maintain blood glucose levels below 200 mg/dL, serum albumin should be at least 3.0 gm/dL and total lymphocyte count should be over 1,500 (10, 11). X-ray scans are necessary to detect any signs of bone involvement, bearing in mind that osteomyelitis appears on X-rays after 3 weeks. When these values are suboptimal, surgery should be postponed, except for the cases with severe infections.

Studies show that this condition is more common in male patients or in patients from rural areas with low economic status who have limited access to medical services and who have a solitary lifestyle, which was also the status of the enrolled patients (3). It is recommended to take into consideration the social status of patients because the treatment is lengthy and it depends on external help.

Foot ulcerative lesions are difficult to heal, so specialized adjuvant treatments are necessary. The common principle of these treatments is the debridement process that ensures the removal of non-viable tissue, leaving behind a deficiency of substance. Debridement must be performed through atraumatic surgical gestures that avoid damage to adjacent healthy tissues. This should be practiced as often as necessary to obtain a clean and prepared wound for reconstruction.

It is considered that a wound is ready to be closed when all the signs of inflammation have disappeared and the wound has the following characteristics: the erythema surrounding the wound has reduced or disappeared, wound edges show no induration and neo-epithelialization areas are present with fresh granulation and a sterile surface. The surface of an evolving wound with healthy granulation tissue decreases by about 10-15% per week (12).

Defects can be healed using delayed primary closure or by using skin grafts, local or pedicled flaps and free flaps.

Choosing the optimal wound closure method is a complex process that requires assessing the viability of adjacent tissues, the size of the wound, its depth as well as the chance of recovery. When the tissues are viable, the granulation is present and the location of the wound is not in a pressure area, it is feasible to apply a skin graft that provides multiple sources of epithelialization. Otherwise, lack of granulation, atonic tissue and localization on a pressure require the use of a local flap. We should also consider the patient's desire to sometimes refuse an intervention, leaving the wound to epithelize secondarily. For the improvement of the healing, platelet rich plasma could also be utilized as an adjuvant therapy (13).

When the ulceration extends to the level of a joint, osteomyelitis should be suspected. This can be clinically verified by introducing a sterile gauze through the ulceration to the bone level or by revealing a clear, viscous fluid that represents the synovial fluid. In this case, an X-ray is needed to assess the bone lesion extension and make a plan for surgery. It is also important to check if any tendon is involved, because the infection can spread proximally and distally along its path.

When soft tissue necrosis, osteomyelitis and uncontrolled infection are present, when the patient complains of unbearable pain, amputation should be considered. Amputation should not be seen or understood as a failure of the treatment, but as a therapeutic solution that removes tissues that could worsen the patient's status. The patient considers this stage as a disability but our role is to provide the necessary support to restore the patient's limb to a functional level that allows him to perform normal daily activities. We must focus on reintroducing them into the community by setting feasible functional goals (14).

On a long term, complications can arise due to the modification of the normal tension forces of the leg, with new ulcerative lesions or stress fractures. Thus, it is recommended that patients wear different orthotic devices to prevent these complications. The long-term goal is to prevent injury to the affected or contralateral leg by maintaining health and glucose blood levels within normal limits and to instruct patients to maintain a proper feet care.

## Conclusions

Diabetic foot ulcer is a severe complication that requires the collaboration of a multidisciplinary team. The surgical treatment should not be avoided because it plays a fundamental role in preventing the spread of infection and further complications. Even if amputation is seen as a debilitating surgery, in some cases, this may prove lifesaving, and a prosthesis is enough to help the patient perform daily activities.

The prevention of diabetic foot ulcers is important and it can be realized through constant clinical evaluation and early treatment of any suspicious lesions, thus lowering the amputation rate and increasing the quality of life.

## Conflict of interest disclosure

There are no known conflicts of interest in the publication of this article. The manuscript was read and approved by all authors.

## Compliance with ethical standards

Any aspect of the work covered in this manuscript has been conducted with the ethical approval of all relevant bodies and that such approvals are acknowledged within the manuscript.

## References

1. Nicholas Katsilambros, Eleftherios Dounis, Konstantinos Makrilakis, Nicholas Tentolouris, Panagiotis Tsapogas; "Atlas of the Diabetic Foot, Second Edition", Wiley-Blackwell, 2010, P: 1-2, 200-202. DOI: 10.1002/9781444317589
2. Cardoso HC, Zara ALSA, Rosa SSRF, Rocha GA, Rocha JVC, de Araújo MCE, Quinzani PF, Barbosa YP, Mrué F. Risk Factors and Diagnosis of Diabetic Foot Ulceration in Users of the Brazilian Public Health System. *J Diabetes Res.* 2019; 2019: 5319892. DOI: 10.1155/2019/5319892.
3. Sørensen MLB, Jansen RB, Wilbek Fabricius T, Jørgensen B, Svendsen OL. Healing of Diabetic Foot Ulcers in Patients Treated at the Copenhagen Wound Healing Center in 1999/2000 and in 2011/2012. *J Diabetes Res.* 2019; 2019: 6429575. DOI: 10.1155/2019/6429575
4. Cozma CN, Raducu L, Avino A, Balcangiu-Stroescu AE, Ionescu D, Jecan CR, Florescu IP. Multidisciplinary management of diabetic foot patients. Surgical Crossroads with Diabetes Mellitus. ISI Proceedings Interdiab Conference March 2019.
5. Katsilambros N, Tentolouris N, Tsapogas P, Dounis E. Atlas of the Diabetic Foot, John Wiley & Sons Ltd, 2003, p: 1-4
6. Cozma CN, Răducu L, Balcangiu-Stroescu AE, Bădițescu DG, Jecan CR. Infections management in venous leg ulcers: our experience. *Romanian Journal of Infectious Disease* 2016; 19(4): 232-6.
7. Michael E. Edmonds, Alethea V.M. Foster, Lee J. Sanders, A practical manual of diabetic foot care. Blackwell Publishing Ltd, 2004, p: 183-185. DOI: 10.1002/9780470988381
8. Raducu L, Balcangiu-Stroescu AE, Stanescu II, Tanasescu MD, Cozma CN, Jecan CR, Badita DG. Use of polyhexanidine in treating chronic wounds. *Revista de Chimie* 2017; 68(9): 2112-2113.
9. Răducu L, Cozma CN, Balcangiu-Stroescu AE, Avino A, Tanasescu MD, Balan DG, Jecan CR. Our experience in Chronic Wound Care with Polyurethane Foam. *Revista de Chimie.* 2018; 69(3): 539-758.

10. Dickhaut SC, Delee JC, Page CP. Nutrition status: importance in predicting wound healing after amputation. *J Bone Joint Surg Am.* 1984; 64(1): 71–75.
11. Balan DG, Stroescu-Balcangiu AE, Tanasescu MD, et al. Nutritional intervention in patients with diabetic renal disease a brief presentation. *Revista de Chimie* 2018; 69(11): 4078-4082.
12. Sheehan P, Jones P, Caselli A, Giurini JM, Veves A. Percent change in wound area of diabetic foot ulcers over a 4-week period is a robust indicator of complete healing in a 12-week prospective trial. *Diabetes Care.* 2003; 26(6): 1879-82.
13. Cozma CN, Raducu L, Jecan CR. Platelet Rich Plasma-mechanism of action and clinical applications. *J Clin Invest Surg.* 2016; 1(2): 41-46.
14. Burgess EM, Romano RL, Zetl JH. The Management of Lower Extremity Amputations, US Government Printing Office, Washington, DC, 1969.