

Prevalence of nodular goiter in patients with breast diseases

Gurushantappa Yalagachin¹, Nishanth Lakshmikantha², Sanjay B. Mashal¹

¹DEPARTMENT OF GENERAL SURGERY, KARNATAKA INSTITUTE OF MEDICAL SCIENCES, HUBLI, INDIA, 580022

²SHANTHI HOSPITAL AND RESEARCH CENTRE (SHRC), 307, 40TH CROSS, 8TH BLOCK, JAYANAGAR, BANGALORE, INDIA, 560070

ABSTRACT



Introduction. Various studies have reported conflicting results regarding the relationship between breast and thyroid diseases. The exact pathogenesis behind this association is not clear. The aim of this study was to determine the prevalence of thyroid disease in patients presenting with breast diseases and to examine whether thyroid screening is required in patients with breast diseases. **Methodology.** All patients attending the department of General Surgery in our institution with breast diseases during the period from December 2015 to September 2017 were enrolled for the study. A thorough clinical examination which included an examination of the neck was done. Thyroid profile and ultrasonography neck were performed in all patients and the pathology in all radiologically diagnosed cases of nodular goiter was confirmed by cytology. **Results.** We had 128 patients with breast diseases enrolled in the study of which 62 (48%) patients had malignant breast disease and 66 (52%) patients had benign breast disease. None of the patients in our study had a palpable thyroid nodule or a diffuse goiter. Of the 61 patients having malignant breast diseases, 26 (42.6%) patients had a radiologically detected thyroid disease and among the 64 patients with benign breast diseases, 10 (15.6%) had radiologically detected thyroid diseases. **Conclusions.** In our study the prevalence of nodular goiter was higher in patients with malignant breast diseases than patients with benign breast diseases. However, this prevalence or clinical relevance is not significant enough to warrant screening for thyroid disease in patients with breast diseases.

Category: Original Research Paper

Received: June 02, 2020

Accepted: August 05, 2020

Keywords:

breast disease, nodular goiter, prevalence, thyroid profile, correlation, screening

*Corresponding author:

Nishanth Lakshmikantha,

Shanthi Hospital and Research Centre (SHRC), 307, 40th Cross, 8th Block, Jayanagar, Bangalore, India, 560070

E-mail: kantha.57@gmail.com

Introduction

Breast cancer is one of the most common cancers in females. It is hormone dependent and can be considered an endocrine system related neoplasm. Thyroid dysfunction is one of the leading causes of endocrinological disorders. It constitutes about 30% to 40% of the patients seen in endocrinological practice. Various studies have reported conflicting results regarding the relationship between breast and thyroid diseases. Few studies have shown a correlation between breast cancer and thyroid diseases [1,2], while other studies have refuted this claim [3]. Thyroid diseases in all its forms, i.e. hyperthyroidism, hypothyroidism, autoimmune thyroiditis, nodular goiter, and thyroid cancer have been associated with breast cancer. The exact pathogenesis behind this association is not very clear, being attributed to the presence of thyroid antibodies and TSH receptors on the breast [4]. The aim of this study was to determine the prevalence of thyroid disease in patients presenting with breast diseases in a tertiary care

center in North Karnataka and to examine whether thyroid screening is required in patients with breast disease.

Materials and Methods

All patients attending the outpatient and inpatient department of General Surgery in Karnataka Institute of Medical Sciences, Hubli with breast diseases during the period from December 2015 to September 2017 were enrolled for the study; a detailed history with an emphasis on symptoms suggestive of hypothyroidism and hyperthyroidism was elicited. A thorough clinical examination which included an examination of the breast, axilla, and neck was done.

In all the patients, diagnosis of the breast disease (benign and malignant) was histologically proven and were recruited for the study before the start of any modality of treatment.

Thyroid profile (T3, T4, and TSH) was estimated in all the patients via an early morning fasting sample and all samples were sent to the same laboratory. Ultrasonography

(USG) neck was performed in all patients by a Senior Radiologist with a Phillips IU 22 machine using a linear probe with 3-12mhz frequency and all radiologically diagnosed cases of nodular goiter were further confirmed histologically by an ultrasound-guided Fine Needle Aspiration Cytology (FNAC) using a 21 G needle. The USG guided aspiration was done by the radiologist himself and the slides were prepared on the spot by pathology postgraduate students. The slides were reviewed and reported by a senior pathologist.

We also looked for associated comorbid conditions like Diabetes Mellitus and Hypertension amongst the patients, and its impact on the association between breast and thyroid diseases.

We excluded patients with thyroid illness diagnosed by clinical history and examination prior to presentation with the breast disease and those who refused to consent to be a part of the study.

Results

A total of 128 patients with breast diseases who fulfilled the inclusion criterion were enrolled in the study of which 62 (48%) patients had malignant breast diseases and 66 (52%) patients had benign breast diseases. Of the 128 patients, 3 (2%) were male and the rest were female. Majority of the patients with benign breast disease presented at less than 30 years of age while most of the patients with malignant breast diseases presented above the age of 45 years (Figure 1).

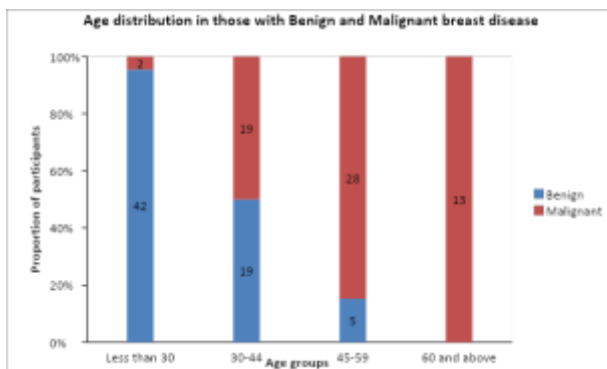


Figure 1. Bar chart depicting age distribution of individuals with breast disease attending our hospital, N=128

Among the patients with benign breast diseases fibroadenoma was the most common diagnosis and was found in 47 (71%) patients. Breast abscess in 9 (12%) patients, gynecomastia in 3 (5%) patients, granulomatous mastitis in 2 (3%) patients, fibrocystic disease in 2 (3%) patients, and ductal papilloma in 1 (1%) patient. There were 62 patients diagnosed with breast carcinoma and all of them were diagnosed as infiltrating ductal carcinoma.

In our study none of the 128 patients enrolled had a palpable thyroid nodule or a diffuse goiter, however on ultrasound of the neck, 34 (26%) patients had features suggestive of nodular goiter, while 2 (2%) patients had features suggestive of Hashimoto's thyroiditis and 92 (72%) patients had a normal thyroid. Of the 61 patients having malignant breast diseases it was found that 26 (42.6%) patients had a radiologically detected thyroid disease and among the 64 patients with benign breast diseases, 10 (15.6%) had radiologically detected thyroid diseases which was statistically significant ($p < 0.001$). Both the cases of Hashimoto's thyroiditis were from the malignant breast disease group.

In our study fasting early morning samples for evaluation of the thyroid profile of all the patients were sent to the same laboratory and the reference values are as follows.

- T3 – 0.7-2.0 ng/ml
- T4 – 4.4-12.0 ug/ml
- TSH – 0.5-5.0 miU/l

There was no statistically significant difference between the values of T3, T4, and TSH amongst the patients with benign and malignant breast diseases. There was no statistically significant difference in the values of T3 and T4 amongst patients with and without thyroid nodules diagnosed on the USG neck. The mean TSH in patients who had a radiologically detected thyroid lesion was 4.65 and in patients with a normal thyroid on USG was 2.6, the difference was statistically significant ($p < 0.001$). There was no significant difference in terms of comorbid conditions like diabetes mellitus and hypertension amongst the patients who had a radiologically detected nodular goiter and those who had a normal thyroid on USG neck (Tables 1, 2).

Table 1. Difference in proportion of thyroid lesion on USG neck between those with Malignant and Benign breast diseases, N=128

Type of Breast disease	Thyroid lesion on USG		Total, n (%)	p value
	Yes, n (%)	No, n (%)		
Benign	10 (15)	56 (85)	66 (100.0)	0.001
Malignant	26(42)	36 (58)	62 (100.0)	
Total	36 (28)	92 (72)	128 (100.0)	

Table 2: Difference in T3, T4 and TSH levels between those with Benign and Malignant breast diseases, N=128, IQR - Interquartile range

Thyroid Profile	Thyroid lesion on USG neck		p value*
	Present, N=36 Median (IQR)	Absent, N= 92 Median (IQR)	
T3 levels(ng/ml)	2.68 (1.15-3.2)	1.84 (1.14-2.8)	0.034
T4 levels(ug/ml)	8.55 (7.6-9.4)	7.6 (4.6-8.6)	0.007
TSH levels(miU/l)	4.65 (3.15-5.2)	2.6 (1.3-3.4)	<0.001

Discussions

In our study we found no association between breast diseases (malignant and benign) and thyroid diseases clinically as none of the patients had a clinically palpable thyroid swelling. Incidental nodular goiter was found in 42% of patients with malignant breast disease and 15% of patients with benign breast disease.

The coexistence of thyroid and breast diseases in a patient has been a subject of debate for a long time. The earliest reports published on the association of breast cancer and thyroid disease dates back to 1896 when Beatson used oophorectomy and thyroid extract to treat patients with breast cancer [5]. There are studies that report the presence of thyroid receptors on the breast and the carcinogenic potential of thyroid hormones through the activation of the MAPK pathway and upregulation of the antiapoptotic gene [6-9]. Vijaykumar et al. indicated that the TSH receptor is expressed in normal breast tissue, and it is significantly increased in human breast tumor samples compared to the control samples [4]. An association between thyroid autoimmunity and breast diseases has been consistently reported. It has been proposed that the immune response might be directed both by tumor and by thyroid tissue [10], or that the tumor and thyroid tissue share common properties, as they both express TPO and the sodium iodide symporter gene [11]. These thyroid autoantibodies have been postulated to act on the receptors

present in both the breast and thyroid and may be responsible for the coexistence of breast and thyroid disorders [12,13].

In our study, though the presence of nodular goiter is higher amongst patients with breast carcinoma (46%) when compared to patients with benign breast diseases (15%) these populations cannot be compared due to the marked difference in age of presentation. Reports show that the size and number of nodules may increase with age [14].

In a study by Turan they reported an incidence of nodular goiter of 20 % amongst patients diagnosed with breast cancer. In this study it was reported that there was no significant difference in grade or type of breast cancer [15]. Smyth et al., in their study reported increased volume of the thyroid gland in 42% of patients with breast diseases, on follow up there was no significant enlargement or involution of the thyroid gland following treatment for breast cancer [10]. Dimitri et al. also reported an incidence of thyroid enlargement in 46% of patients with breast carcinoma when compared to the control population [16]. In our study, 42% of the patients with breast carcinoma had a nodular goiter.

Smyth et al. reported an enlarged thyroid gland in 17% of patients with benign breast diseases. In our study, 15% of patients with benign breast diseases had a nodular goiter [10]. Dimitri et al reported a higher incidence of thyroid enlargement (49%) in patients with benign breast diseases [16]. The above-mentioned comparisons are depicted in Table 3.

Table 3. Prevalence of thyroid abnormality in patients with breast diseases of different etiologies

STUDIES	Thyroid abnormality with Malignant breast diseases	Thyroid abnormality in patients with Benign breast diseases
Dimitri A, et al.	46.4 %	49 %
P.P.A Smyth et al.	41.5 %	17.2 %
Our study.	42 %	15 %

The prevalence of a palpable nodular goiter amongst the adult population ranges from 4-7%, whereas the prevalence noted at autopsy is around 50% [17]. It is to be noted that in our study none of the patients had a clinically palpable thyroid gland and the nodular goiter

was a radiological diagnosis. USG of the neck is highly sensitive to pick up nodules and studies have shown that the capacity to pick up incidental nodules is as high as 50% [14]. The risk of a nodular goiter turning malignant is around 4-6%.

Management of a nodular goiter is dependent on various factors like the size of the goiter, TSH values, and the presence of compressive symptoms. In our study all the patients had a clinically undetectable nodular goiter in the euthyroid state for which the treatment is best left alone [17]. That brings us to wonder if there is a need to investigate all patients with breast diseases with an ultrasound of the neck, FNAC, thyroid profile, and antithyroid antibodies considering the fact that even if there is an association between these organs, they do not alter the management or prognosis of the disease affecting either one of them. In our study none of the patients were treated for their nodular goiter as none of them were hypothyroid on evaluation of their thyroid profile. However, further long-term studies with larger numbers and age-matched control groups with follow up is needed.

Limitations of our study was that the two groups of patients with malignant and benign breast diseases were not comparable in age. Due to lack of availability we could not get antithyroid antibodies tested for the patients as done in previous studies.

Conclusions

In our study the prevalence of nodular goiter was higher in patients with malignant breast diseases as compared to patients with benign breast diseases. However, this prevalence or clinical relevance is not significant enough to warrant routine screening for thyroid disease in patients presenting with either benign or malignant breast disease.

Abbreviations:

FNAC - Fine Needle Aspiration Cytology

USG - Ultrasonography

TSH – Thyroid stimulating hormone

Conflict of interest disclosure

There are no known conflicts of interest in the publication of this article. The manuscript was read and approved by all authors.

Compliance with ethical standards

Any aspect of the work covered in this manuscript has been conducted with the ethical approval of all relevant bodies and that such approvals are acknowledged within the manuscript.

Acknowledgments

We would like to thank all the staff from the Department of Surgery, Karnataka Institute of Medical Sciences, Hubli in their unending cooperation for the study. The authors would like to acknowledge the help of Dr. G. C. Patil, Professor and Head, and the staff of the

Department of Radiology in our institute for their help in radiological services for the study. We also thank the Postgraduate students and the staff of the Department of Pathology for their support for the cytological and histopathological reporting of samples. We thank Dr. Bharath, Dr. Divya and Dr. Manasa for their help in data collection. We would also like to acknowledge the help of Dr. K Lakshman, Consultant Laparoscopic and GI Surgeon in helping us in the write up of the manuscript.

References

1. Turken O, NarIn Y, DemIrbas S, et al. Breast cancer in association with thyroid disorders. *Breast Cancer Res.* 2003;5(5):R110-R113. doi:10.1186/bcr609
2. Rasmusson B, Feldt-Rasmussen U, Hegedüs L, Perrild H, Bech K, Høier-Madsen M. Thyroid function in patients with breast cancer. *Eur J Cancer Clin Oncol.* 1987;23(5):553-556. doi:10.1016/0277-5379(87)90319-1
3. Moossa AR, Evans DA, Brewer AC. Thyroid status and breast cancer. Reappraisal of an old relationship. *Ann R Coll Surg Engl.* 1973;53(3):178-188.
4. Govindaraj V, Yaduvanshi NS, Krishnamachar H, Rao AJ. Expression of thyroid-stimulating hormone receptor, octamer-binding transcription factor 4, and intracisternal A particle-promoted polypeptide in human breast cancer tissues. *Horm Mol Biol Clin Invest.* 2012;9(3):173-178. doi:10.1515/hmbci-2011-0130
5. Love RR, Philips J. Oophorectomy for breast cancer: history revisited. *J Natl Cancer Inst.* 2002;94(19):1433-1434. doi:10.1093/jnci/94.19.1433
6. Charalampoudis P, Agrogiannis G, Kontzoglou K, Kouraklis G, Sotiropoulos GC. Thyroid hormone receptor alpha (TRa) tissue expression in ductal invasive breast cancer: A study combining quantitative immunohistochemistry with digital slide image analysis. *Eur J Surg Oncol.* 2017;43(8):1428-1432. doi:10.1016/j.ejso.2017.05.012
7. Khan SR, Chaker L, Ruitter R, et al. Thyroid Function and Cancer Risk: The Rotterdam Study. *J Clin Endocrinol Metab.* 2016;101(12):5030-5036. doi: 10.1210/jc.2016-2104
8. Kress E, Samarut J, Plateroti M. Thyroid hormones and the control of cell proliferation or cell differentiation: paradox or duality?. *Mol Cell Endocrinol.* 2009;313(1-2):36-49. doi:10.1016/j.mce.2009.08.028
9. Lin HY, Glinsky GV, Mousa SA, Davis PJ. Thyroid hormone and anti-apoptosis in tumor cells. *Oncotarget.* 2015;6(17):14735-14743. doi:10.18632/oncotarget.4023
10. Smyth PP. Autoimmune thyroid disease and breast cancer: a chance association?. *J Endocrinol Invest.* 2000;23(1):42-43. doi:10.1007/BF03343675

11. Spitzweg C, Joba W, Eisenmenger W, Heufelder AE. Analysis of human sodium iodide symporter gene expression in extrathyroidal tissues and cloning of its complementary deoxyribonucleic acids from salivary gland, mammary gland, and gastric mucosa. *J Clin Endocrinol Metab.* 1998; 83(5): 1746-1751. doi: 10.1210/jcem.83.5.4839
12. Ron E, Curtis R, Hoffman DA, Flannery JT. Multiple primary breast and thyroid cancer. *Br J Cancer.* 1984;49(1):87-92. doi:10.1038/bjc.1984.13
13. Dumont JE, Maenhaut C, Pirson I, Baptist M, Roger PP. Growth factors controlling the thyroid gland. *Baillieres Clin Endocrinol Metab.* 1991;5(4):727-754. doi:10.1016/s0950-351x(10)80012-6
14. Popoveniuc G, Jonklaas J. Thyroid nodules. *Med Clin North Am.* 2012; 96(2): 329-349. doi: 10.1016/j.mcna.2012.02.002
15. Turan E, Sevinç B. Relation between Thyroid Disease and Breast Cancer. *Int J Cancer Clin Res.* 2016;3(2):052.
16. Adamopoulos DA, Vassilaros S, Kapolla N, Papadiamantis J, Georgiakodis F, Michalakis A. Thyroid disease in patients with benign and malignant mastopathy. *Cancer.* 1986;57(1):125-128.
17. Hoang JK, Nguyen XV, Davies L. Overdiagnosis of thyroid cancer: answers to five key questions. *Acad Radiol.* 2015;22(8):1024-1029. doi:10.1016/j.acra.2015.01.019